

# **Clinical Evidence for Cervical Myelopathy due to Chiari Malformation and Spinal Stenosis in a Non-randomized Group of Patients with the Diagnosis of Fibromyalgia**

DAN S HEFFEZ MD<sup>1,2</sup>, RUTH E ROSS PHD<sup>1</sup>, YVONNE SHADE- ZELDOW PHD<sup>1</sup>,  
KONSTANTINOS KOSTAS PHD<sup>1</sup>, SAGAR SHAH BS MPH<sup>1</sup>, ROBERT GOTTSCHALK  
ND/FNP<sup>1</sup>, DEAN A ELIAS MD<sup>1</sup>, ALAN SHEPARD MD<sup>1</sup>, SUE E LEURGANS PHD<sup>2</sup>,  
CHARITY G MOORE PHD<sup>2,3</sup>

CHICAGO INSTITUTE OF NEUROSURGERY AND NEURORESEARCH<sup>1</sup> AND RUSH  
PRESBYTERIAN ST. LUKE'S MEDICAL CENTER<sup>2</sup> CHICAGO, ILLINOIS AND THE  
UNIVERSITY OF SOUTH CAROLINA<sup>3</sup>, COLUMBIA, SC

**Eur Spine J. 2004 Oct;13(6):516-23. Epub 2004 Apr 9**

Running title: Cervical myelopathy and fibromyalgia

Address Correspondence to: Dan S Heffez MD FRCS

Heffez Neurosurgical Associates SC,

2900 North Lake Shore Drive, 12<sup>th</sup> floor

Chicago, IL, 60657

Email: [dheffez@sbcglobal.net](mailto:dheffez@sbcglobal.net)

(773) 281-4402

fax: (773) 281-4472

SUPPORTED IN PART BY A GRANT FROM THE NATIONAL FIBROMYALGIA RESEARCH  
ASSOCIATION WHICH PLAYED NO ROLE IN THE DESIGN OR EXECUTION OF THIS WORK.

## ABSTRACT

**Objective:** While patients with fibromyalgia report symptoms consistent with cervical myelopathy, a detailed neurological evaluation is not routine. We sought to determine if patients with fibromyalgia manifest objective neurological signs of cervical myelopathy.

**Methods:** 270 patients, 18 years and older, who carried the diagnosis of fibromyalgia but who had *no previously recognized* neurological disease underwent detailed clinical neurological and neuroradiological evaluation for the prevalence of objective evidence of cervical myelopathy and radiological evidence of cerebellar tonsillar herniation (Chiari 1 malformation) or cervical spinal canal stenosis.

**Results:** Patients were primarily women (87%) of mean age 44 years who had been symptomatic for 8 years (std dev 6.3 yrs). The predominant complaints were neck/back pain (95%), fatigue (95%), exertional fatigue (96%), cognitive impairment (92%), instability of gait (85%), grip weakness (83%), paresthesiae (80%), dizziness (71%) and numbness (69%). Eighty-eight percent of patients reported worsening symptoms with neck extension. The neurological examination was consistent with cervical myelopathy: upper thoracic spinothalamic sensory level (83%), hyper-reflexia (64%), inversion of the radial periosteal reflex (57%), positive Romberg sign (28%), ankle clonus (25%), positive Hoffman sign (26%), impaired tandem walk (23%), dysmetria (15%) and disdiadochokinesia (13%). MRI and contrast enhanced CT imaging of the cervical spine revealed stenosis. The mean antero-posterior (AP) spinal canal diameter at C2/3, C3/4, C4/5, C5/6, C6/7 and C7/T1 was 13.5, 11.8, 11.5, 10.4, 11.3 and 14.5 mm respectively, (CT images). In 46% of patients, the AP spinal diameter at C5/6 measured 10mm or less with the neck positioned in mild extension, i.e. clinically significant spinal canal stenosis. MRI of the brain revealed tonsillar ectopia > 5mm in 20% of patients (mean =7.1+/- 1.8mm), i.e Chiari 1 malformation.

**Conclusion:** Our findings indicate that some patients who carry the diagnosis of fibromyalgia have both signs and symptoms consistent with cervical myelopathy, most likely resulting from spinal cord compression. We recommend detailed neurological evaluation of patients with fibromyalgia in order to exclude cervical myelopathy, a potentially treatable condition.

*Key words: Fibromyalgia, cervical myelopathy, spinal stenosis, Chiari 1 malformation*

## **Introduction**

Fibromyalgia is a syndrome characterized by diffuse chronic pain [8,13,53,55]. The American College of Rheumatology has established diagnostic criteria for fibromyalgia that include a history of unexplained pain of three months duration, widespread distribution of pain to involve both sides of the body above and below the waist and the presence of 11 or more of 18 specified symmetrical tender points [55]. The overall prevalence of fibromyalgia as defined above is 2% with a prevalence of 3.4% among women and 0.5% among men [8,13,54]. By these estimates, approximately six million Americans suffer from fibromyalgia. The diagnostic criteria have been helpful in distinguishing fibromyalgia from other chronic pain states but they have not advanced the understanding of its etiology. Accordingly, fibromyalgia remains a syndrome and not a disease. In addition to the widespread pain, patients complain of a wide variety of symptoms, including overwhelming fatigue exacerbated by exertion, as well as headache, dizziness, cognitive difficulties, instability of gait, limb numbness and paresthesiae [8,13,22,53]. Some physicians have come to view the syndrome as a somatization disorder because of these numerous and apparently unrelated complaints, and because fibromyalgia fails to fit the biomedical cause-effect model [5,25].

Many of the symptoms reported by fibromyalgia patients are identical to those reported by patients diagnosed with either Chiari 1 malformation or with cervical myelopathy due to spinal stenosis, (spondylotic cervical myelopathy), two well-defined neurological disorders [1,18,38]. Therefore, we evaluated a cohort of patients who carried the diagnosis of fibromyalgia for objective evidence of cervical myelopathy. The results of these evaluations are the subject of this report.

## **Methods**

### **Patients**

Two hundred and seventy (270) consecutive patients who carried the diagnosis of fibromyalgia were evaluated between September 1998 and May 2001. The sole requirement for referral was that the patient carry the diagnosis of fibromyalgia, a diagnosis not independently confirmed at our institution. In every case, the diagnosis of fibromyalgia had been established by

the patient's rheumatologist (66% of patients), neurologist or primary care physician. Most patients were self-referred in order to determine if there was a neurological basis for their symptoms. These patients had had no previous neurological or neuroradiological investigation. They had sought us out because of our nationally publicized interest in a potential neurological basis for fibromyalgia symptoms. Others had previously undergone magnetic resonance imaging (MRI) of their cervical spine, which had shown some degree of spinal stenosis and/or cerebellar tonsillar ectopia which was felt by their treating physicians to be of no clinical significance. As such the patients represented a non-randomly selected cohort of fibromyalgia sufferers not necessarily representative of all fibromyalgia patients. *However, no patient was referred for the evaluation of a recognized clinical neurological finding nor was anybody referred for the express purpose of evaluating a neuroradiological finding. Not a single patient had been previously diagnosed with cervical myelopathy.*

On initial evaluation, patients completed a questionnaire detailing their symptoms, current medications and past medical consultations. A diagram depicting the distribution of the patient's body pain and an analogue pain severity scale were completed. Patients were evaluated by a neurologist (AS) and/or a neurosurgeon (DSH) who, independently of each other, performed a neurological examination and recorded the findings on a standardized form in order to insure that every patient was evaluated in the same manner. There was no communication between the neurosurgeon and the neurologist until after completion of the patient's entire evaluation. All data was gathered prospectively and entered into a relational database, (MS Access, Microsoft Corporation, Redmond, WA). A psychologist and a rehabilitation team comprised of physical, occupational and speech therapists also evaluated each of the patients. The evaluation protocol was approved by the IRB of Rush Presbyterian St. Luke's Hospital and informed consent was obtained from each patient.

## **Radiological Imaging**

Every patient underwent magnetic resonance imaging of the brain with special attention to the foramen magnum. The MRI scans were performed on a General Electric (location) Signa system, 1.5 Tesla field strength, 256x256 matrix. Standard axial, sagittal and coronal T1 weighted

images, (6mm thick with 5% gap, TR=550-600msec, TE=14msec, 60% flip angle) were obtained. T2 weighted axial images were also obtained, (6mm thickness, 5% gap, TR=5700msec, double echo TE=14 and 90 msec). Oblique T2 weighted images through the foramen magnum were obtained using a 2 D spin echo fast spin echo technique, (TE=85, TR=3600, 3mm slice thickness, 0.5mm gap, 256x256 matrix). For the purpose of determining the position of the cerebellar tonsils the lower lip of the foramen magnum was defined as extending from the lowest cortical bone of the clivus anteriorly (basion) to the lowest cortical bone at the opistion posteriorly on the mid sagittal MRI image. The position of the most caudal point of the tonsil(s) relative to the inferior lip of the foramen magnum was measured from the midsagittal MRI slice, as is the convention [3]. A position rostral to the plane of the foramen magnum was given a negative value in mm. Location of the cerebellar tonsil(s) within the foramen magnum was given a value of 0. Caudal displacement was expressed in mm with a positive value.

MRI scan of the cervical spine was performed in those patients who had not previously undergone this test in order to identify any intrinsic spinal cord lesion capable of causing myelopathy. MRI was performed on a 1.5Tesla unit. Imaging sequences included sagittal T1 weighted conventional spin-echo images (500TR/16TE, 4mm thick slices, 0.4mm spacing, 192x256 matrix), sagittal fast spin-echo T2 weighted images, (4000 TR/102eff TE, 16 echo train, 3mm thick slices, 0.5mm spacing, 256x256 matrix), axial T1 weighted conventional spin-echo images, (650 TR/16 TE, 4mm thick slices, 0.4mm spacing, 192x256 matrix), and axial gradient-echo T2\* images, (800 TR/20 TE/25 degree flip angle, 4mm thick slices, 0.4mm spacing, 192x256 matrix). All sagittal images were obtained at a 22cm field of view and all axial images were obtained at a 20cm field of view displayed with a 1.5 magnification. Axial images were obtained parallel to each disc space.

Every patient also underwent computed tomographic (CT) imaging of the cervical spine. CT imaging of the cervical spine was performed following intravenous infusion of 150 ml of non-ionic contrast (300mg of iodine/ml) over 2 minutes. A scanning time of 3-4 seconds at 120Kv and 200 Ma was utilized. Contiguous, axial sections, 3 mm in thickness were obtained from the level of the mid posterior fossa to the first thoracic vertebra. Soft tissue and bone windows were obtained. For the initial set of images, the patient's head was positioned in the head-holder such that the neck would be in the neutral or slightly flexed orientation as is the convention for both MRI and CT imaging. The gantry angle was selected in order to obtain images perpendicular to

the spine at each level. A second set of images was obtained with the patient's shoulders elevated on a pad so as to extend the neck. The gantry angle was altered to obtain images perpendicular to the spine at each level despite the exaggerated lordosis attendant on neck extension. The mid-sagittal antero-posterior dimension of the spinal canal was determined at the level of the intervertebral disc space on both neutral and extended neck images [42]. The actual diameter available to accommodate the spinal cord, dura mater and cerebrospinal fluid was determined by measuring the distance between the posterior most projection of the intervertebral disc anteriorly and the ligamentum flavum or lamina posteriorly as determined by which structure was most contiguous to the dorsal surface of the dura.

MRI and CT images were individually scanned into a Pentium III personal computer using a Umax power look III scanner, (Umax Technologies Inc., Fremont CA). One of two independent observers, unrelated to the medical evaluation or treatment of the patients and unaware of any clinical neurological findings, made measurements of the position of the cerebellar tonsils and the mid-sagittal antero-posterior spinal canal diameters using SigmaScan Pro software, version 5.0, (SPSS, Richmond CA). Measurements of the mid-sagittal antero-posterior spinal canal diameter were made such that the largest possible diameter was recorded so as not to overstate the degree of stenosis.

## **Results**

### **Clinical Findings**

Two hundred seventy (270) patients were evaluated. Eighty-six percent of the patients were women. Ninety-seven percent were Caucasian. The mean age was 44 years (SD=11 years). The mean duration of symptoms was 8 years (std dev 6.3 yrs). Fifty-nine percent of patients reported antecedent craniospinal trauma within 3-6 months of the onset of symptoms. The trauma in question varied in severity from a whiplash to a mild otherwise innocuous blunt trauma. There were no cases of fracture or dislocation of the cervical spine nor of skull fracture. On average, the patients had consulted 10 different medical specialists during the course of their illness. Patients were taking a mean of 4.8 medications, (including but not limited to opiate and non-opiate analgesics, benzodiazepines, antidepressants, sedative hypnotics and muscle relaxants), for the relief of symptoms related to fibromyalgia. Forty-one percent of patients had at least a college

education. Sixty-eight percent of patients had left their job as a direct result of their illness. The predominant complaints were neck/back pain (95%), fatigue (95%), exertional fatigue (96%), cognitive impairment (92%), instability of gait (85%), subjective grip weakness (83%), paresthesiae (80%), dizziness (71%) and numbness of the hands/feet (69%). Eighty-eight percent of patients reported worsening symptoms with neck extension. The symptom prevalence is reported in **table 1**.

The neurological findings detected on physical examination and their prevalence in this cohort of patients are listed in **table 1**. An upper thoracic spinothalamic sensory level (T3-T6) was the most prevalent finding. It was noted in 83% of patients. Typically, we detected hyperalgesia and allodynia to a cold or lightly applied pinprick stimulus below a dermatome level. Rarely, a suspended band of hypesthesia to cold or pinprick stimulus was detected between the third and seventh thoracic dermatomes. The second most common neurological finding, (noted in 64% of patients), was hyper-reflexia, often asymmetrical in distribution and involving any combination of limbs. Recruitment, (the pathological spread of reflexes beyond the muscle being tested), including inversion of the radial periosteal reflex was observed in 57% of patients. Other objective neurological findings included positive Romberg sign (28%), varying degrees of ankle clonus (25%), positive Hoffman sign (26%), impaired tandem walk (23%), dysmetria (15%) and disidiadochokinesia (13%). The patients were examined first with the neck in the neutral and subsequently in the flexed and then in the extended positions. Neck extension and neck flexion resulted in immediate accentuation of abnormal pyramidal track findings in 88% and 73% of patients respectively, suggesting a mechanical etiology for the abnormal neurological findings. In those patients who were examined by both the neurologist and the neurosurgeon, the neurologist reported a higher prevalence of such findings as hyper-reflexia, Hoffman sign, Romberg sign and impaired tandem walk, (**table 2**). The neurosurgeon was in a position to consider a surgical intervention for myelopathy, and therefore adhered to an arbitrarily high threshold before considering any neurological finding as abnormal. For instance, even if a patient was clearly unsteady on performing the Romberg or tandem walk test but did not actually fall, the result was rated as normal by the neurosurgeon. The neurosurgeon found a higher prevalence of clonus because he designated clonus as present if there were three or more beats on ankle dorsiflexion. The neurologist designated clonus only if it was sustained. The neurosurgeon also designated a

higher prevalence of weakness. This can be a very subjective finding and was therefore never relied upon in concluding that the patient did or did not have myelopathy.

## **Radiological findings**

The MRI images of the brain did not show any consistent intrinsic disease of the brain parenchyma. The only consistent finding was the caudal displacement of the cerebellar tonsils. The mean position of the cerebellar tonsils as measured on the mid sagittal MRI image was 1.1 mm (SD=4.4mm) below the rim of the foramen magnum. In 38% of patients the tonsillar herniation exceeded 3mm, (mean 5.6, SD=2.1 mm). In 20% of patients tonsillar ectopia exceeded 5 mm (mean=7.1, SD=1.8mm), i.e. Chiari 1 malformation.

MRI and contrast enhanced CT imaging of the cervical spine revealed a narrow spinal canal, i.e. stenosis. The mean anteroposterior (AP) segmental spinal canal diameter as measured on MRI, CT-neutral and CT-extension images is shown in **figure 1**. In 23% of patients, the AP mid-sagittal spinal canal diameter at the level of the C5/6 intervertebral disc measured 10mm or less with the neck positioned neutral, i.e. clinically significant spinal stenosis. The AP spinal canal diameter at the level of the C5/6 intervertebral disc measured 10mm or less in 46% of patients when the cervical spine was imaged with the neck positioned in extension (**figure 2**). MR imaging of the cervical spine did not reveal any consistent intrinsic spinal cord disease with the exception of signal hyper-intensity at the level of spondylotic spinal cord compression noted on the T2 sequence images in some patients. These changes were generally mild, not sharply demarcated and most evident on axial images. One patient had a small syrinx in the upper thoracic spinal cord.

## **Discussion**

Fibromyalgia is a form of nonarticular rheumatism characterized by widespread musculoskeletal pain. Its symptoms are one of the most common reasons for referral to a rheumatologist. By some estimates it affects 6 million Americans [8,9,24]. The absence of any consistent routine pathological laboratory or radiological finding has led some observers to conclude that fibromyalgia is a form of psychogenic rheumatism [24,25]. It is not unusual for the patients to be dismissed as somatizers [5,24,25]. And yet, patients complain of a number of symptoms that could be neurological in nature and are typical of those associated with the Chiari 1



malformation and with cervical myelopathy due to spinal stenosis. In fact, a recent publication reported that some patients with the Chiari malformation had been previously diagnosed with fibromyalgia [38]. The symptoms common to these disorders include pain, headache, clumsiness, grip weakness, instability of gait, dizziness, paresthesiae and numbness [1,18,19,21,38]. Cognitive impairment including short-term memory loss and difficulty with concentration, (commonly referred as “fibro fog” among fibromyalgia patients), has also been reported by patients with the Chiari 1 malformation [38]. Muscular fatigue worsened by exertion is a well-described symptom of cervical myelopathy [1,18]. In a recent report of 364 patients with documented symptomatic Chiari 1 malformation, 57% were noted to complain of chronic fatigue [38]. In this same series of patients 59% had previously been misdiagnosed with a psychogenic illness [38]. Bowel and bladder dysfunction including constipation, urinary urgency and frequency are also consistent with cervical myelopathy [1,18]. Despite the apparent similarity of symptoms, no specific objective neurological abnormalities have ever been described in fibromyalgia patients. Furthermore, a detailed neurological examination to exclude underlying neurological disease is not generally considered essential before rendering a diagnosis of fibromyalgia.

In a cohort of 270 patients diagnosed with fibromyalgia but not previously recognized to have a neurological disorder, we found objective neurological evidence diagnostic of cervical myelopathy. A high thoracic spinothalamic sensory disturbance was identified in 83% of patients. An upper thoracic sensory level has been described as a sign of cervical myelopathy [18,47]. The same dermatome level was commonly identified on the anterior and posterior thorax, strongly suggesting a true neuro-anatomical level. Hyperactive deep tendon reflexes were identified in the upper and /or lower extremities in 64% of patients. In addition to hyper-reflexia, recruitment and inversion of reflexes were observed in 57% of patients. Recruitment is an upper motor neuron sign of pyramidal tract dysfunction [1,17]. Inversion of the radial periosteal reflex is noted when the brachioradialis reflex is diminished or absent in conjunction with a contraction of the flexor digitorum muscles. This finding is felt to be virtually diagnostic of myelopathy due to extrinsic compression of the spinal cord at the level of the fifth or sixth cervical vertebra [1,17]. Other findings diagnostic of or consistent with cervical myelopathy included a positive Hoffman sign, positive Romberg sign, impaired tandem walk and ankle clonus [1,8]. The abnormal pyramidal tract findings were accentuated by neck extension and flexion, maneuvers known to aggravate spinal cord compression in the face of spinal stenosis or ventral cervical disc protrusion or bone

spurs [1,4,7,26,40,41,42,50]. The bilateral involvement of the upper and lower extremities and the presence of a high thoracic sensory level would localize the neurological abnormalities to the cervical spinal cord or cervicomedullary junction and would be consistent with, if not diagnostic of, the clinical diagnosis of cervical myelopathy. It is important to note that a second clinical diagnosis, even one that may be associated with pain, does not exclude the diagnosis of fibromyalgia.

Cervical myelopathy is a clinical diagnosis based on history and neurological examination and not a radiological diagnosis. Symptoms of myelopathy are variable and can be quite vague, often leading to initial misdiagnosis [1,15,16,18,34,38,47]. The etiology of the myelopathy is determined from laboratory studies and neuroradiological investigation. Included in the differential diagnosis is cervicomedullary compression at the foramen magnum due to the Chiari 1 malformation and cervical spinal cord compression due to congenital or spondylotic stenosis of the spinal canal [1,18,38]. Brain et al first described cervical spondylosis as a cause of cervical myelopathy [12]. It has since come to be recognized as the most common cause of cervical myelopathy [1,11,15,16,18,34]. The presence of a Chiari 1 malformation or of spinal stenosis does not imply myelopathy. Both structural abnormalities may be entirely asymptomatic. However, in the setting of cervical myelopathy, the finding of Chiari 1 malformation or of spinal stenosis should be considered as a possible cause of the neurological disorder.

Imaging of the brain and cervical spine in our cohort of patients revealed two potential structural causes of cervical myelopathy- cervical stenosis and cerebellar tonsillar ectopia. The MRI of the brain revealed cerebellar tonsillar ectopia with the mean degree of caudal tonsillar herniation equal to 1.1mm. This contrasts with the normal position of the cerebellar tonsil as reported in the literature, (1+/-1.9mm above the foramen magnum) [3]. This degree of tonsillar ectopia falls below the threshold consistent with the radiological diagnosis of the Chiari type 1 malformation [3,21,38]. In 20% of our patients a radiological diagnosis of the Chiari 1 malformation was made based on tonsillar ectopia in excess of 5 mm, the accepted radiological standard. This prevalence contrasts sharply with that reported by Meadows et al who reviewed the brain and cervical spine MRI's of 22,591 patients. They could identify only 175 patients in whom tonsillar ectopia exceeded 5 mm, i.e. a prevalence of 0.77% [36].

While CT with intravenous contrast infusion is not frequently used to image the cervical spine, it has certain advantages over MR imaging. These advantages include better resolution of bony anatomy and lack of exaggeration of spinal canal stenosis [28,29,30,43,44,51]. In addition, dynamic imaging of the spine in the axial plane using MRI has certain shortcomings; sagittal images, (which are inferior to axial images for the assessment of stenosis), are almost exclusively used [30,40,41]. These shortcomings relate to the relationship between the extended or flexed neck and the surface magnetic coils, and are avoided by using CT technology [30,40]. Conversely, CT is inferior to MRI for imaging the spinal cord itself [30]. The use of CT with intravenous contrast enhancement for the purpose of imaging cervical disc herniation or stenosis has been previously described [28,29,30,35,44,48,51].

The CT scan of the cervical spine revealed cervical stenosis which was accentuated by neck extension. Neck extension is known to reduce the antero-posterior spinal canal diameter as a result of increased disc protrusion, infolding of the ligamentum flavum and the gliding action facilitated by the horizontal orientation of the facet articular surfaces [4,26,41,42,48,50]. As the cervical spine is a dynamic structure, we felt that dynamic imaging would be more informative than static imaging. The importance of imaging the cervical spine in extension in order to increase the sensitivity of detecting canal stenosis in myelopathic patients has been described [26,40,41]. In our cohort of patients, the mean antero-posterior spinal canal measurements throughout the cervical spine were smaller than those observed in normal controls as reported in the literature [35,48] (**figure 1**). Stanley et al, using CT imaging, found the mean AP mid-sagittal diameter to range from 14mm at C3 to 15mm at C7 in 52 volunteers with no neurological symptoms. The volunteers were equally divided between males and females and were of mean age 42 years [48], comparable to the mean age of our study population. Matsuura et al, again using CT imaging, found the mean AP mid-sagittal diameter of the spinal canal to range from 14.4mm at C6 to 15.2mm at C3 in 100 normal control subjects of mean age 28.8 years. There were 47 males and 53 females in the control group. There was no significant difference in the spinal measurements between men and women [35]. In our cohort of patients, the mean AP mid-sagittal diameter ranged from a low of 11.4mm at C5/6 to a high of 12.7mm at C4/5 when the neck was imaged in the neutral position. Measurements were on average 0.6 to 0.9 mm smaller when the neck was imaged in extension. Our mean AP mid-sagittal measurement at the C7/T1 level, (14.9mm), was in agreement with that reported by both Stanley et al, (15mm) and Matsuura et al, (14.6mm). The AP

mid-sagittal diameter at the C5/6 intervertebral disc space measured 10mm or less in 23% of patients with the neck in neutral alignment and 46% of patients with the neck placed in extension (**figure 2**). A mid-sagittal diameter of 10mm is acknowledged as stenotic and consistent with symptomatic spinal cord compression, i.e. cervical myelopathy [11,20,27,28,35,48,50]. In fact, Stanley et al concluded that 10mm must be considered the lower limit of normal for the AP mid-sagittal diameter of the cervical spine as imaged by CT scan. In their series of normal controls, no patient had a spinal diameter which measured less than 11mm from C3 through C5 [48]. In the series reported by Matsuura, no normal control patient had a spinal diameter less than 13mm from C3 to C6 [35]. If 14mm is taken as the normal mid-sagittal spinal canal diameter, then only 2 of our 270 patients had a normal spinal canal dimension at each level. If 13mm is taken as the normal mid-sagittal spinal canal diameter, then only 4 patients had a normal spinal canal dimension at each level. It is important to note that our measurements of the mid-sagittal antero-posterior spinal canal diameter were made such that the largest possible diameter was recorded at each level so as not to overstate the degree of stenosis. MRI images tended to slightly exaggerate the degree of spinal stenosis as compared to the CT images performed with the neck in the neutral alignment (**figure 1**). The tendency of MRI imaging to accentuate spinal stenosis has also been described [28,30].

It is important to re-iterate that our cohort of patients was not randomly selected for evaluation from among fibromyalgia sufferers. Therefore, the actual prevalence of cervical myelopathy, Chiari 1 malformation and spinal stenosis in the general fibromyalgia population remains unknown. It is possible that these three problems are over-represented in our non-randomly selected cohort. The diagnosis of fibromyalgia was not independently confirmed at our institution. If our patients had been misdiagnosed with fibromyalgia, then our data argue for a neurological evaluation to exclude cervical myelopathy before rendering a diagnosis of fibromyalgia. If our patients had been correctly diagnosed with fibromyalgia, then our data argue for a possible link between fibromyalgia symptoms and cervical myelopathy, further confirming the need for a neurological examination. As 66% of our patients were diagnosed with fibromyalgia by a rheumatologist, we can perhaps assume that these patients met ACR criteria for the diagnosis. Between 60%-70% of patients had hyperreflexia, 80% had some signs of a sensory level and 57% showed signs of pathological spread of reflexes. This would suggest that many patients who met ACR criteria for fibromyalgia also showed signs of cervical myelopathy. There are research

findings suggesting that fibromyalgia may be a neurological disorder characterized by “central sensitization”. Abnormalities in pain processing [6,31], central pain modulation [33,37] and secondary hyperalgesia [2] have been reported. There are also reports of reduced thalamic blood flow [32,39], and elevated levels of nerve growth factor [23] and the neurotransmitter substance P [45,52] in the cerebrospinal fluid of fibromyalgia patients. More recently, Thimineur et al reported an elevation of thermal perception thresholds in patients with Chiari 1 malformation or cervical spinal stenosis in association with chronic pain as compared to chronic pain sufferers who did not have any evidence of neurological disease. They also reported a higher prevalence of fibromyalgia, chronic regional pain syndrome and temporomandibular joint syndrome in patients with Chiari 1 malformation as compared to chronic pain sufferers with no evidence of central nervous system disease. These investigators postulate an impairment of the descending inhibitory projections from the rostral ventral medulla to the spinal cord dorsal horn and trigeminal nucleus caudalis as the mechanism for the hyperalgesia [49].

The prevalence of antecedent craniocervical trauma was higher in our cohort (59%) than is generally reported among fibromyalgia patients, perhaps reflecting our specific inquiry regarding a history of trauma however mild. However, an association between neck injury and subsequent development of fibromyalgia has been reported. Wolfe reported a 40% prevalence of neck injury and a 31% prevalence of back injury in a series of patients with fibromyalgia [56]. Buskila et al reported that the incidence of fibromyalgia was 13 times greater following neck injury than following lower extremity injury [14].

In conclusion, we have identified neurological findings consistent with cervical myelopathy in a selected cohort of 270 patients previously diagnosed with fibromyalgia. The neurological disorder had not been previously detected despite the fact that the patients had, on average, consulted 10 doctors prior to seeing us. This is the first report documenting objective neurological abnormalities in patients with fibromyalgia. Neuroradiological findings were consistent with a structural cause(s) for the myelopathy -i.e. spondylotic cervical stenosis and/or Chiari type 1 malformation. Spondylotic cervical myelopathy and the Chiari 1 malformation are treatable conditions, but the success of treatment is related to the duration of illness [1,10,15,16,18,34,38,46,47]. Therefore, it is important to exclude cervical myelopathy due to Chiari 1 malformation and/or spinal stenosis in patients presenting with the symptoms of fibromyalgia. A detailed neurological examination should be incorporated into the evaluation of all

patients with fibromyalgia. Evidence of cervical myelopathy would warrant appropriate neuroradiological imaging and neurological referral.

Acknowledgements: We would like to thank Drs. Daniel Malone, Scott Kale, Robert Bennett, Peter Rowe and Norman Kohn for their extensive review and very constructive criticism of the manuscript and Dr. Michael Huckman for review of issues relating to radiological imaging. We would like to thank Dr. Kareem Foloshade and Ms. Melissa Martinez for meticulous data entry.

## References

1. An HS (1998) Clinical presentation of discogenic neck pain, radiculopathy and myelopathy. In: The Cervical Spine Research Society editorial committee. The Cervical Spine 3<sup>rd</sup> ed. Lippincott-Raven, Philadelphia, pp 755-764
2. Arroyo JF and Cohen ML (1993) Abnormal response to electrocutaneous stimulation in fibromyalgia. *J Rheumatol* 20:1925-1931
3. Barkovich AJ, Wippold FJ, Sherman JL, et al (1986) Significance of cerebellar tonsillar position on MR. *AJNR* 7:795-799
4. Barnes MP and Saunders M (1984) The effect of cervical mobility on the natural history of cervical spondylotic myelopathy. *J Neurology, Neurosurgery and Psychiatry* 47:17-20
5. Barsky AJ and Borus JF (1999) Functional somatic syndromes. *Annals of Internal Medicine* 130:910-921
6. Bendtsen L, Norregaard J, Jensen R et al (1997) Evidence of qualitatively altered nociception in patients with fibromyalgia. *Arthritis Rheum* 40:98-102
7. Benner BG (1998) Etiology and pathogenesis of discogenic neck pain. In: The Cervical Spine Research Society editorial committee. 3<sup>rd</sup> ed. The Cervical Spine. Lippincott-Raven, Philadelphia, pp 735-740
8. Bennett RM (1999) Fibromyalgia. In: Wall P.D. and Melzack R (eds) Textbook of Pain, 4<sup>th</sup> edition, Churchill Livingstone, Edinburgh, London, New York, pp 579-599
9. Bennett RM (1995) Fibromyalgia: the commonest cause of widespread pain. *Comprehensive Therapy* 21:269-275
10. Blumberg KD and Simeone FA (1992) Indications for surgery in cervical myelopathy: anterior versus posterior approach. In Rothman RH and Simeone FA eds. The Spine. 3<sup>rd</sup> edition. WB Saunders, Philadelphia, pp 613-625
11. Bohlman HH and Emery SE (1988) The pathophysiology of cervical spondylosis and myelopathy. *Spine* 13:843-846
12. Brain RW, Northfield D, Wilkinson M (1952) The neurological manifestations of cervical spondylosis. *Brain* 75:187-225
13. Buchwald D (1996) Fibromyalgia and chronic fatigue syndrome: similarities and differences. *Rheumatic Disease Clinics of North America* 22:219-243
14. Buskila D, Neumann L, Vaisberg G et al (1997) Increased rates of fibromyalgia following cervical spine injury. A controlled study of 161 cases of traumatic injury. *Arthritis Rheum* 40:446-452
15. Clarke E and Robinson PK (1956) Cervical myelopathy: a complication of cervical spondylosis. *Brain* 79:483-510
16. Crandall PH and Batzdorf U (1966) Cervical spondylotic myelopathy. *J. Neurosurgery* 25:57-66.
17. Dejong RN (1979) The muscle stretch reflexes. In: Dejong RN and Magee KR (eds) The Neurological Examination. Harper and Row, Hagerstown MD, pp 431-445
18. Dillin WH and Watkins RG (1992) Clinical syndromes of cervical myelopathy. In: Rothman RH and Simeone FA (eds) The Spine. 3<sup>rd</sup> edition. WB Saunders, Philadelphia, pp 560-570
19. Dyste GN, Menezes AH, VanGilder JC (1989) Symptomatic Chiari malformations, an analysis of presentation, management and long-term outcome. *J Neurosurg* 71:159-168
20. Edwards WC, LaRocca SH (1985) The developmental segmental sagittal diameter in combined cervical and lumbar stenosis. *Spine* 10:42-49
21. Elster AD and Chen MYM (1992) Chiari 1 malformations: clinical and radiologic reappraisal. *Radiology* 183:347-353



22. Forseth KO, Forre O and Gran JT (1999) A 5.5 year prospective study of self-reported musculoskeletal pain and of fibromyalgia in a female population: significance and natural history. *Clinical Rheumatology* 18:114-121
23. Giovengo SL, Russell IJ, Larson AA (1999) Increased concentrations of nerve growth factor in cerebrospinal fluid of patients with fibromyalgia. *J Rheumatol* 26:1564-1569
24. Goldenberg DL (1987) Fibromyalgia syndrome an emerging but controversial condition. *JAMA* 257: 2782-2787
25. Goldenberg DL (1996) What is the future of fibromyalgia? *Rheumatic Disease Clinics of North America* 22:393-406
26. Graham CB, Wippold FJ, Bae KT et al (2001) Comparison of CT myelography performed in the prone and supine positions in the detection of cervical spinal stenosis. *Clinical Radiology* 56:35-39
27. Heller JG and Pedlow FX (1998) Anatomy of the cervical spine. In: *Cervical Spine Research Society Editorial Committee, The Cervical Spine*. 3rd ed. Lippincott-Raven, Philadelphia, pp 3-35
28. Herzog RJ, Wiens JJ, Dillingham MF et al (1991) Normal cervical spine morphometry and cervical spinal stenosis in asymptomatic professional football players. Plain film radiography, multiplanar computed tomography and magnetic resonance imaging. *Spine* 16:s178-186
29. Jahnke RW and Hart BL (1991) Cervical stenosis, spondylosis and herniated disc disease. *RCNA* 29:777-791
30. Kaiser JA and Holland BA (1998) Imaging of the cervical spine. *Spine* 23:2701-2712
31. Kosek E, Ekholm J, Hansson P (1996) Sensory dysfunction in fibromyalgia patients with implications for pathogenic mechanisms. *Pain* 68:375-383
32. Kwiatek R, Barnden L, Tedman R, et al (2000) Regional cerebral blood flow in fibromyalgia: single photon-emission computed tomography evidence of reduction in the pontine tegmentum and thalami. *Arthritis Rheum* 43:2823-2833
33. Lautenbacher S, Rollman GB (1997) Possible deficiencies of pain modulation in fibromyalgia. *Clin J Pain* 13:189-196
34. Lees F and Turner JWA (1963) Natural history and prognosis of cervical spondylosis. *British Medical Journal* 2:1607-1610
35. Matsuura P, Waters RL, Adkins RH et al (1989) Comparison of computerized tomography parameters of the cervical spine in normal control subjects and spinal cord injured patients. *JBJS* 71:183-188
36. Meadows J, Kraut M, Guarnieri M et al (2000) Asymptomatic Chiari type 1 malformation identified on magnetic resonance imaging. *J Neurosurg* 92:920-926
37. Mense S (2000) Neurobiological concepts of fibromyalgia—the possible role of descending spinal tracts. *Scand J Rheumatol Suppl* 113:24-29
38. Milhorat TH, Chou MW, Trinidad EM, et al (1999) Chiari 1 malformation redefined: clinical and radiological findings in 364 symptomatic patients. *Neurosurgery* 44:1005-1017
39. Mountz JM, Bradley LA, Modell JG et al (1995) Fibromyalgia in women. Abnormalities of regional cerebral blood flow in the thalamus and caudate nucleus are associated with low pain threshold levels. *Arthritis Rheum* 38:926-938
40. Muhle C, Metzner J, Weinert D, et al (1999) Kinematic MR imaging in surgical management of cervical disc disease, spondylosis and spondylotic myelopathy. *Acta Radiologica* 40:146-153
41. Muhle C, Wiskirchen J, Weinert D, et al (1998) Biomechanical aspects of the subarachnoid space and cervical cord in healthy individuals examined with kinematic magnetic resonance imaging. *Spine* 23:556-567
42. Parke WW (1988) Correlative anatomy of cervical spondylotic myelopathy. *Spine* 13:831-837

43. Reul J, Gievers B, Weis J et al (1995) Assessment of the narrow cervical spinal canal: a prospective comparison of MRI, myelography and CT-myelography. *Neuroradiology* 37:187-191
44. Russel EJ (1995) Computed tomography and myelography in the evaluation of cervical degenerative disease. *Neuroimaging Clinics of NA* 5:329-348
45. Russell IJ, Orr MD, Littman B, et al (1994) elevated cerebrospinal fluid levels of substance P in patients with the fibromyalgia syndrome. *Arthritis Rheum* 37:1593-1601
46. Sampath P, Bendebba M, Davis JD et al (2000) Outcome of patients treated for cervical myelopathy. *Spine* 25:670-676
47. Simmons Z, Biller J, Beck DW et al (1986) Painless compressive cervical myelopathy and false localizing sensory findings. *Spine* 11:869-872
48. Stanley JH, Schabel SI, Frey GD et al (1986) Quantitative analysis of the cervical spinal canal by computed tomography. *Neuroradiology* 28:139-143
49. Thimineur M, Kitaj M, Kravitz E et al (2002) Functional abnormalities of the cervical cord and lower medulla and their effect on pain: observations in chronic pain patients with incidental mild Chiari 1 malformation and moderate to severe cervical cord compression. *Clin J Pain* 18:171-179
50. Torg JS, Pavlov H, Genuario SE, et al (1986) Neurapaxia of the spinal cord with transient quadriplegia. *JBJS* 68-A:1354-1370
51. Ulrich CG (1998) Computed tomography and myelography of the cervical spine. In: *Cervical Spine Research Society editorial committee. The Cervical Spine*. 3rd ed. Lippincott-Raven, Philadelphia, pp 253-270
52. Vaeroy H, Helle R, Forre O et al (1988) Elevated CSF levels of substance P and high incidence of Raynaud phenomenon in patients with fibromyalgia: new features for diagnosis. *Pain* 32:21-26
53. Wallace DJ (1997) The fibromyalgia syndrome. *Annals of Medicine* 29:9-21
54. Wolfe F, Ross K, Anderson J (1995) The prevalence and characteristics of fibromyalgia in the general population. *Arthritis and Rheumatism* 38:19-28
55. Wolfe F, Smythe HA, Yunus MB et al (1990) The American College of Rheumatology, 1990 criteria for the classification of fibromyalgia: report of the Multicenter Criteria Committee. *Arthritis and Rheumatism* 33:160-172
56. Wolfe F (1986) The clinical syndrome of fibrositis. *Am J Med* 81 suppl 3A:7-14

**Table 1:** Prevalence of symptoms and neurological signs in 270 patients with the diagnosis of fibromyalgia

<b>Fibromyalgia Symptom</b>	<b>prevalence in 270 patients (%)</b>	<b>Neurological sign</b>	<b>prevalence in 270 patients (%)***</b>
Fatigue**	96	Sensory level*	83
Body pain*	95	Hyper-reflexia**	64
Cognitive impairment	92	Recruitment	57
Generalized weakness*	92	Absent gag reflex	37
Headache****	90	Romberg sign	28
Gait instability*	85	Hoffman sign	26
Grip weakness*	83	Clonus	25
Photophobia	83	Impaired tandem walk	23
Hand clumsiness*	80	Weakness**	22
Paresthesiae*	80	Dysmetria	15
Irritable bowel syndrome***	77	Impaired position sense	14
Dizziness****	71	Cranial nerve V	8
Numbness*	69	Ataxia	8
Blurred vision or diplopia	65	Nystagmus	6
Disorientation	54	Cranial nerve XII	4
Chronic nausea	40		

\*known symptom of

Myelopathy

\*\***muscular** fatigue is a known symptom of myelopathy

\*\*\*bowel /bladder dysfunction are associated with myelopathy

\*\*\*\* known symptom of cervical spondylosis and Chiari

\*cold and pin stimulus

\*\*in at least 1 limb

\*\*\*as determined by the neurosurgeon

**Table 2:** Prevalence of Common Neurological Signs of Myelopathy by Examiner  
(n=138 patients examined independently by neurologist and neurosurgeon)

Neurological Sign	Neurologist	Neurosurgeon
	(% prevalence)	(%prevalence)
Hyper-reflexia	70	63
Hoffman sign*	47	29
Romberg sign	39	27
Impaired Tandem walk	33	23
Weakness*	4	22
Clonus*	7	30
Nystagmus*	17	6
Dysmetria	15	16
Disdiadochokinesia*	26	15
Ataxia	10	6

\*=statistically significant difference  
between observers  
( $p=.02$ ), McNemar's test

**Figure 1:** Graph comparing mean antero-posterior spinal canal diameters in anatomical specimens, (ref.27), with diameters measured on intravenous contrast enhanced CT and MRI images of the cervical spine in our cohort of fibromyalgia patients and in normal controls, (CT normal 1, ref. 35; CT normal 2, ref.48).

**Figure 2:** Graph showing percentage of patients with the diagnosis of fibromyalgia in whom the mid-sagittal spinal canal diameter measured 10 mm or less. Images were obtained using both CT and MRI imaging techniques. Ten millimeters is the accepted threshold for the radiological diagnosis of clinically relevant spinal stenosis.

Figure 1

### Mean Mid-Sagittal Spinal Canal Diameter (mm)

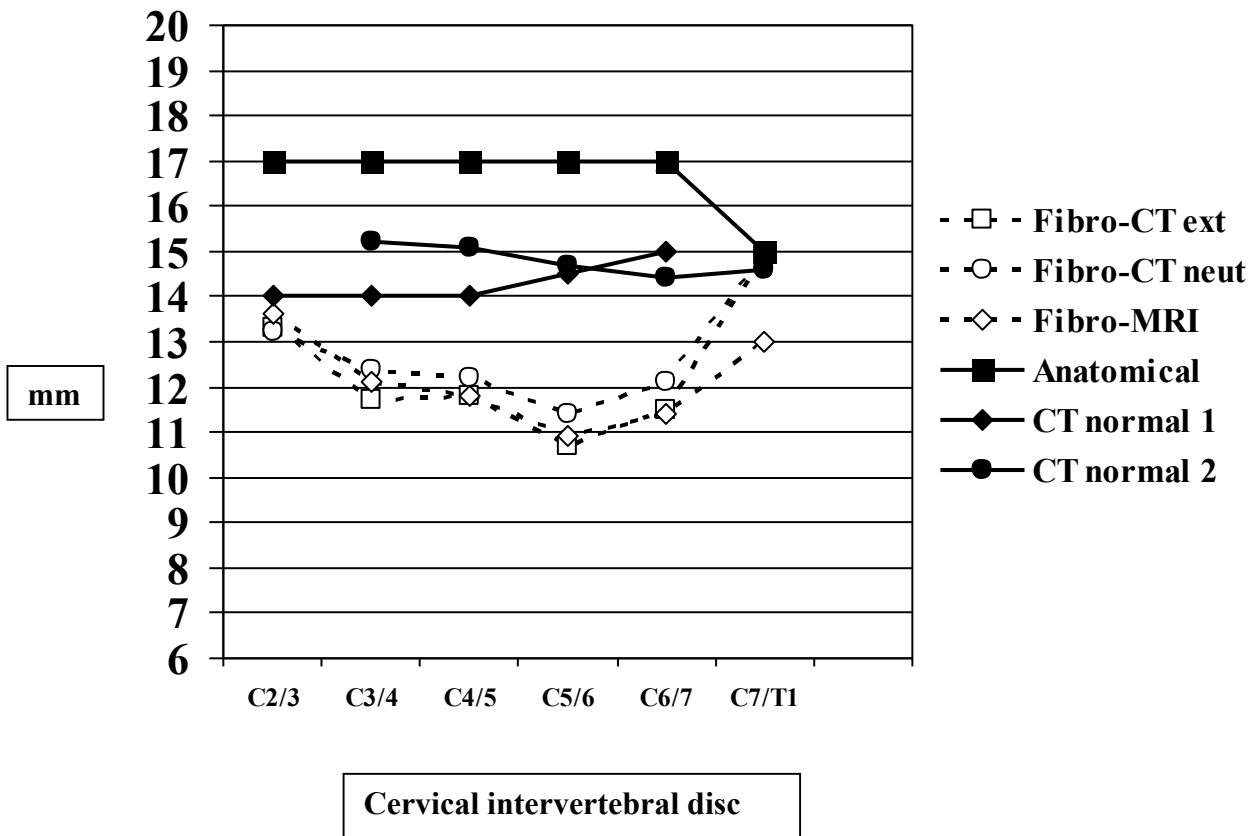


Figure 2

Mid-Sagittal Spinal Canal Diameter 10 mm or less  
(% of patients)

